Received: 15 July 2022 | Revised: 5 October 2022 | Accepted: 16 October 2022

DOI: 10.1002/rcs.2472

ORIGINAL ARTICLE

The International Journal of Medical Robotics and Computer Assisted Surgery

WILEY

# Clinical safety and efficacy of a fully automated robot for magnetic resonance imaging-guided breast biopsy

Mehran Anvari[1] | Trevor Chapman[1] | Karen Barlow[1] | Tyler Cookson[1] | Carolyn Van Toen[2] | Tim Fielding[2]

[1]Centre for Surgical Invention and Innovation (CSii), McMaster University, Hamilton, Ontario, Canada

[2]MCDonald Detwiller & Associates (MDA), Brampton, Ontario, Canada

**Correspondence**
Mehran Anvari, Centre for Surgical Invention and Innovation (CSii), 50 Charlton Ave E, Rm T2140, Hamilton, ON L8N 4A6, Canada.
Email: anvari@mcmaster.ca

**Funding information**
Network Centres of Excellence; Centres of Excellence for Commercialization and Research program

## Abstract

**Background:** Magnetic resonance imaging (MRI)-guided biopsies are an accurate, but technically challenging, method for screening and diagnosis of breast lesions. This study assesses the safety and efficacy of an Image Guided Automated Robot (IGAR) in performing breast biopsies compared to manual procedures.

**Methods:** Safety was determined from adverse events (AEs) and device deficiencies. Efficacy was assessed using targeting accuracy, number of successful biopsies, pain and scar scores, patient discomfort, and radiologist-determined ease-of-use.

**Results:** All seven procedures in phase I were successfully and safely completed with no AEs and one device deficiency. The 23 IGAR biopsies in phase II outperformed the 18 manual biopsies in 1-week pain scores ($p = 0.027$), scarring at 1-week ($p = 0.035$), 1-month ($p = 0.004$), and components of comfort and ease-of-use. Phase II had seven and three AEs in the IGAR and manual groups, respectively ($p = 0.317$), with no serious AEs and nine device deficiencies.

**Conclusions:** The IGAR system is safe and effective for breast biopsy procedures. The results from these trials indicate the IGAR system as a potentially viable alternative to manual breast biopsy procedures.

KEYWORDS
automated robot, biopsy, breast cancer, lesion, MRI-compatible

## 1 | INTRODUCTION

Breast cancer is the most common cancer affecting women in North America.[1,2] While mammography remains the standard for screening and indexing breast cancer, its sensitivity is variable and lower in high-risk patients and patients with dense breasts.[3,4] It is recommended that these two groups should receive annual screening with breast magnetic resonance imaging (MRI), in addition to annual mammography.[5] The ability of breast MRI to identify malignancy is superb, with sensitivity reported as high as 98%–100%. However, its specificity has been reported as low as 45%,[6–8] which highlights the need for MRI-guided breast biopsy for accurate diagnosis and staging.[9]

Magnetic resonance imaging-guided breast biopsy remains as the most accurate screening and diagnosis tool for small breast lesions not visible by ultrasound. While either manual calculation or software can be used to plan the trajectory of the biopsy tools, manual breast biopsy procedures are extremely technical and are ultimately reliant on the dexterity of the care provider to place and advance the biopsy tools. The success is dependent on the skill level of the radiologist involved and repeat biopsy is required in about 10% of MRI- and ultrasound-guided biopsies and about 26% of mammographically-guided biopsies.[10–12]

Advances in surgical robotics are providing a pathway for improved healthcare quality, specifically in cancer screening and diagnosis. Other MR-compatible robotic manipulators for image-

guided biopsy have been shown to demonstrate safe and accurate biopsies in breast, prostate, liver, brain and back.[13–19] The Image Guided Automated Robot (IGAR)-Breast system is the first of its kind to offer automated needlescopic breast biopsy procedures for breast cancer diagnosis that can be used in a clinical setting as an alternative to the current standard of care, largely removing reliance on the dexterity of the care provider and reducing the margin for human error. This system has previously demonstrated accurate robotic control, MR compatibility and MR safe operation without jeopardising image quality.[20]

Automating surgical procedures is expected to improve outcomes due to increased precision of instruments and by removing elements of the procedure that are subject to potential human error. Automation will also address the learning curve involved with learning new procedures, allowing for better results with lower experiential skillsets.

The Centre for Surgical Invention and Innovation (CSii) is a not-for-profit research institute hosted by McMaster University, which is involved in the design and development of novel medical robotic platforms. The first system to be developed for clinical use is an IGAR capable of automated targeting and positioning of a variety of interventional tools to small lesions inside the body using real time coordinates obtained from a variety of imaging modalities. The first application of IGAR is a fully automated MRI-guided biopsy of lesions in the breast. Image Guided Automated Robot-Breast has 6° of freedom (3° of linear motion and 3° of rotational motion) and is capable of automated anaesthetic injection, biopsy tool insertion, and biopsy tool roll. Tele-guidance capability enables the user (radiologist) to control the manipulator arm from within the MRI suite using a control pendant or from the MRI control room in an automated fashion. Further development and the use of live video feed will enhance this capability, providing those living in remote communities with access to services that would otherwise be inaccessible. Image Guided Automated Robot-Breast is expected to offer a more accurate, quicker, and less painful procedure with less overall MRI suite time. The accuracy and repeatability of IGAR-Breast has been validated in free space and within the MRI environment using inanimate gel models.[20] In this study, we present the results from both our phase I and phase II clinical trials to demonstrate safety, accuracy, and efficacy of the IGAR-Breast system relative to the standard of care manual technique.

## 2 | MATERIALS AND METHODS

### 2.1 | Investigational device

Image Guided Automated Robot-Breast has three main subsystems: (1) the IGAR subsystem, (2) the patient support structure, and (3) the set of custom tool adaptors (Figure 1).[20] The IGAR subsystem includes a *manipulator* capable of positioning a tool to a target inside of a patient, a *workstation* for viewing MR images and planning the intervention, and a *bedside pendant controller* that receives commands from the *workstation* to ensure that the manipulator moves safely and accurately to the desired position. The IGAR manipulator is placed near the head of the MR bed. Image Guided Automated Robot's power supply, motion controller, motor amplifiers, and safety circuits are contained within a radiofrequency-shielded enclosure in a control cart, which is kept in the MR suite. The control cart is connected to the workstation in the MR control room through a fibre-optic cable, which passes through the waveguide. The patient support structure maintains the patient in a prone orientation (Figure 2). Two openings in the surface of the support allow the breasts to hang down into the imaging region. The imaging region is bracketed with radiofrequency coils (GE 1.5T Lateral Array Coils and GE 1.5T Sentinelle Medial Array Coil, 2 Ch) to receive the signals required to construct the MR image. The patient support permits the IGAR manipulator to dock in an accurate and repeatable manner in locations that allow access to the breast from the superior direction. The docking is accurate and repeatable to create a known mechanical link between the

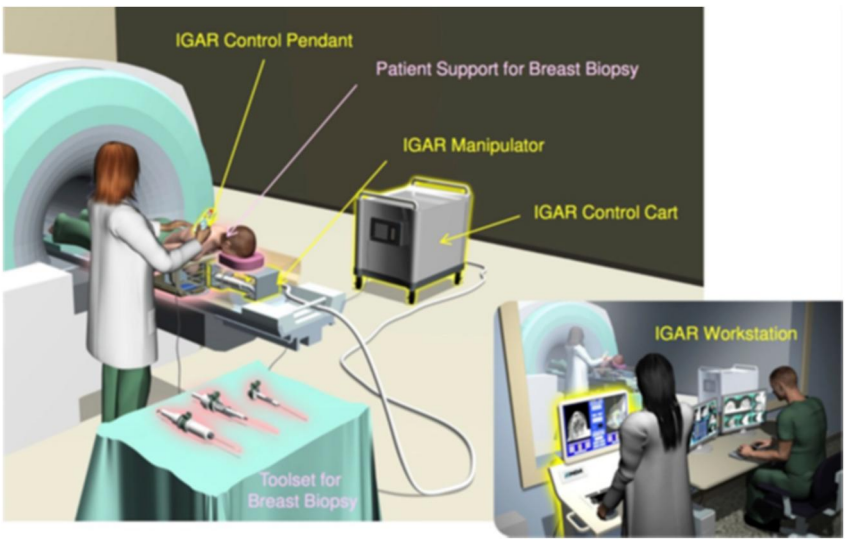


**FIGURE 1** Image Guided Automated Robot (IGAR)-Breast system elements

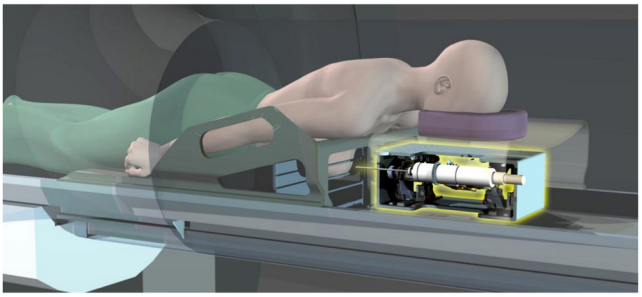

**FIGURE 2** Patient set up: The Image Guided Automated Robot (IGAR) manipulator is docked to a modified patient support structure. The patient lies supine and their head rests on top of the manipulator.

manipulator and fiducial markers embedded in the patient support table. This subsystem also contains the breast restraint, which holds the breast firm and immobile during imaging and intervention. The breast restraint features parallel plates and compresses the breast in the superior-inferior plane.

A set of custom 3-D printed tool holders and adaptors are used to interface off-the-shelf tools (Needle guide, anaesthesia syringe and needle, ATEC Introducer Localization System Kit and ATEC Vaccuum Assisted Biopsy [VAB] Handset) with the IGAR manipulator. Using these adaptors and holders, tools are attached to a mounting arm on the manipulator that runs along an insertion track that is driven by piezoelectric motors (Figure 3). The alignment of the insertion track is achieved through the action of linear and rotary drive assemblies contained within the manipulator casing. Translation that is applied evenly across the insertion track results in linear movement, while differential motion between the front and back of the insertion track results in horizontal angular motion and vertical angle. Together with rotation, these movements give the IGAR 6° of freedom.

**FIGURE 3** IGAR-Breast manipulator is positioned on a Docking Tray which attaches to the Patient Support on an MRI table. A VAB tool is mounted to the robotic arm of the manipulator using a VAB tool adaptor. The Anaesthesia needle with tool adaptor and handheld pendent are also shown. IGAR, Image Guided Automated Robot; MRI, magnetic resonance imaging; VAB, Vaccuum Assisted Biopsy.

### 2.1.1 | IGAR breast biopsy procedure

The patient is positioned on the IGAR-Breast patient support structure (prone orientation with breasts immobilised) and medial-lateral radio-frequency coils are positioned as closely as possible to the target volume. A gadolinium-based contrast agent is injected intravenously to aid in targeting the lesion and a single time-course of contrast-enhanced MR images is acquired in the usual manner; all subsequent images are compared back to this data set to confirm accurate targeting of the lesion. The radiologist identifies the target lesion by reviewing MR images in the usual manner and uses the IGAR workstation to select the most appropriate trajectory to the target.

The radiologist attaches the anaesthesia needle to the manipulator using the anaesthesia needle adaptor. The radiologist then uses the control pendant, to insert the anaesthesia needle and inject anaesthetic along the desired trajectory. Next, a guide cannula is slipped over the outside of a trocar and the trocar adaptor is locked on to the manipulator arm. The trocar is inserted into the breast using the control pendant. Once the cannula is in the desired position, the IGAR manipulator retracts the trocar while the cannula is held in place using a secondary fixture (cannula holder). Placement of the cannula is verified by manually inserting a plastic obturator into the cannula and acquiring a second series of MR images. Retargeting requirement is assessed at this stage by the radiologist.

Once accurate placement of the cannula is confirmed, the VAB tool (ATEC 0914-20MR or ATEC 0914-12MR) is attached to the IGAR manipulator using the VAB tool adaptor and advanced to the correct target location within the cannula (i.e., fully inserted such that the biopsy aperture is at the target site). Samples are collected at different clock-face positions as the VAB tool rotates around its central axis. This rotation is automated, with the option of manual control over the different clock-face positions. Retargeting or rebiopsy requirement is reassessed at this stage by the radiologist.

Once sampling is complete, the VAB tool is removed for final verification imaging. An off-the-shelf clip is placed manually to mark the biopsy site for future reference. The cannula is manually removed from the patient and compression applied to the wound. The intravenous line is removed, bandages applied and after care provided as necessary.

### 2.1.2 | Safety features of the investigational device

MR compatibility and safety of the IGAR device has been previously published.[20] Several safety features have been incorporated in the design of the IGAR system.

1. **Fail-safe design**: Hardware and software fail in a safe condition when a single fault occurs. The 'safe' state of the IGAR System is defined by: (i) All motors are disabled and powered off; (ii) The manipulator immediately stops in place; (iii) A tool can be manually removed from the patient and the manipulator. Faults can be triggered by the system during software safety loops, or by the MR Technologist or Radiologist activating an emergency stop (E-stop) when an emergency arises.
2. **Emergency Stop (E-stop)**: There are two E-stop buttons that can be activated by the user at any time to place the IGAR System in a 'safe' state, as defined above. These emergency buttons are located on the IGAR control cart (magnet room) and the handheld control pendant (magnet room). When there is an emergency, the operator(s) of the IGAR System must activate the E-stop button on either the IGAR Control Cart or the IGAR Pendant by immediately pressing the red button down. The E-stop button will remain latched—even if the operator's hand is removed—after activation and requires the user to physically reset it (by twisting the knob) to restart operation of the IGAR System. Tools can be manually retracted/released from the patient while the system is in the 'safe' state. The IGAR System will remain in a 'safe' state after an E-stop is reset.
3. **Restricted Workspace:** The reachable workspace for biopsy intervention is limited by hardware reach and software collision boundaries. A pneumothorax, whereby the IGAR has moved tools resulting in puncture of the lung, should not be possible given the reachable workspace under normal use.
4. **Ease of Patient Extraction:** The hardware is designed to enable emergency egress of a patient in distress.
5. **Interlocks on Manipulator Motion**: The position base joints and insertion joints are driven independently to increase the positioning accuracy of the tool tip and to control motion when in contact with a patient.
6. **Runaway Detection:** Runaway detection and redundant position sensing is applied to all joints.
7. **Operator Input for Critical Functions:** Any motion, when in contact with a patient, requires the operator to continuously press a button on the IGAR Pendant, otherwise motion stops.

### 2.1.3 | Safety study—Phase I

The Phase I trial is a prospective, open-label, single-arm, single-site study designed to preliminarily demonstrate the safety and efficacy of the IGAR-Breast system in performing MRI-guided targeting and intervention of breast tissue in female patients indicated for MRI-guided biopsy. Female patients ≥18 years with suspected or confirmed breast cancer that presented to the breast cancer clinic in Quebec City requiring an MRI-guided breast biopsy for diagnosis or staging that were able to give free and informed consent were approached for this study. Patients were excluded if (1) MRI-guided breast biopsy was not possible due to patient size, location of the lesion, size of the lesion, or any other reason, (2) patient refused the procedure for any reason, (3) patient was unwilling to complete the associated study questionnaire or follow-up visits, (4) patient was pregnant or planned on becoming pregnant within the study period. Patients with childbearing potential must have had a negative serum pregnancy test at screening and use a medically acceptable form of contraception to be included.

## 2.2 | Demographics and outcomes

Demographic characteristics such as age, weight, body mass index (BMI), ethnicity, medical history of procedures and conditions, and regular medication use were collected and assessed for potential confounders. Collected outcomes for the Phase I study included any adverse events, patient pain scores from the Short-Form McGill Pain Questionnaire,[21] subject discomfort using the Acceptance questionnaire, conversion rate to a manual procedure, anaesthetic information, number of attempts to obtain a sample, length of procedure, and radiologist ease-of-use from the Usability questionnaire. The Acceptance Questionnaire used a scale of 1–5, with 1 being 'strongly agree' and 5 being 'strongly disagree'. The Usability Questionnaire used a scale of 1–5, with 1 being 'very easy' and 5 being 'very difficult.' Absolute positioning error was determined by the difference between the target lesion's three-dimensional position and that of the obturator tip in the confirmation MR image.

### 2.2.1 | Efficacy study—Phase II

The Phase II IGAR clinical trial is a prospective, open-label, double-arm, dual-site cohort study. Female patients who presented to the breast cancer clinic in Quebec City and Hamilton with suspected breast cancer requiring MRI-guided breast biopsy for diagnosis or staging were screened for eligibility. Female subjects ≥18 years who required MRI-guided breast biopsy for diagnosis or staging, and were able to tolerate MRI procedures were eligible to participate. Female subjects who met any one of the following criteria were excluded from the study: (1) subjects who refuse or are unable to give free and informed consent, (2) subjects for whom the investigator determines manual MRI-guided

breast biopsy is not possible (size of patient, location of lesion, size of breast, etc.), (3) subjects for whom the investigator determines IGAR-Breast enabled MRI-guided breast biopsy is not possible (size of patient, location of lesion, size of breast, etc.), (4) subjects with multiple breast lesions to be biopsied, (5) subjects who are pregnant or who plan to become pregnant during the course of the study.

## 2.3 | Participant recruitment

Eligible participants were approached to participate in the study. The consented participants were then invited to undergo IGAR-Breast enabled biopsy for assessment of the primary outcome measure. Subjects who refused to have the procedure done using IGAR-Breast proceeded with a routine manual MRI-guided breast biopsy as per standard practice. All consenting patients were followed up for the assessment of the secondary outcome measures. Upon consent, each IGAR-Breast participant underwent an automated breast biopsy at their local site using the IGAR-Breast system, while the radiologist operated the system. Image Guided Automated Robot procedures were performed at either Hôpital du Saint Sacrement in Quebec City, QC or at St. Joseph Healthcare in Hamilton, ON.

## 2.4 | Outcomes

The primary outcome measure is the frequency of successful breast biopsy. The secondary outcome measures were compared between IGAR and manual MRI-guided breast biopsies.

Secondary outcome measures included procedural times, number of attempts required to reach the target lesion, absolute positioning error determined by the difference between the target lesion's three-dimensional position and that of the obturator tip in the confirmation MR image, subject pain from the Short-Form McGill Pain Questionnaire,[21] subject discomfort from the patient Acceptance Questionnaire, cosmetic outcome using the Vancouver Scar Scale,[22] number of anaesthetic injections and volume of anaesthetic used, and radiologist assessment of ease-of-use from the Usability Questionnaire relative to the manual technique. The Acceptance and Usability questionnaires were scored the same as described above in phase I.

Pain experienced by patients immediately after the procedure and 1 week after the procedure was measured on the McGill Short Form Pain scale for all subjects in the trial. Cosmetic appearance of the biopsy site was measured on the Vancouver Scar Scale at 1 week and 1 month after the procedure. Differences between manual and IGAR biopsies were compared in terms of the procedure duration, pain scores, scar scores, and questionnaires.

## 2.5 | Statistical analysis

Intention to treat analysis was performed. Normality was assessed using the Shapiro-Wilk test. Normally distributed data is presented as mean ± standard deviation (SD) and compared using two-tailed, unpaired, independent *t*-tests while non-normally distributed data is presented as median (interquartile range [IQR]) and were evaluated using Mann-Whitney *U* tests. The level of significance was set at 0.05.

Patient demographics are presented as count (*N*) and proportion of total biopsies within their group. Due to the smaller sample sizes, Fisher's exact test was used to assess differences in categorical demographic variables, such as ethnicity, medical history, and medication use. Age, weight, and BMI are presented as mean (SD) and were compared using independent samples *t*-tests. The 95% confidence intervals for successful biopsy were calculated using the Wilson exact method. The secondary outcome measures of procedural times, number of attempts required to reach the target lesion, targeting accuracy, patient pain and discomfort, cosmetic outcome will be compared using independent samples *t*-test or Mann-Whitney *U* test. All statistical analysis was performed using IBM Corp. Released 2020. IBM SPSS Statistics for Windows, Version 27.0. Armonk, NY: IBM Corp.

# 3 | RESULTS

## 3.1 | Safety study—Phase I

Nine patients were consented for the phase I IGAR clinical trial; however, two patients did not undergo IGAR biopsy. One could not fit in the MRI due to their size and required an ultrasound-guided biopsy, while the other did not fit properly with the IGAR patient support table. The remaining seven patients all had successful biopsies by IGAR. There were two procedural deviations in the study. Firstly, one patient presented with two lesions. One lesion was biopsied using IGAR and the other was completed manually. Second, one patient experienced a device deficiency when the vacuum-assisted biopsy (VAB) tool adaptor failed to roll. The roll was assisted manually and the procedure was completed as planned.

### 3.1.1 | Phase I—Demographics

Patient demographics for the seven phase I patients are reported in Table 1. The average age was 55 ± 14 years and mean BMI was 22.6 ± 4.6 kg/m$^2$. All seven patients were Caucasian. No patients reported a history of breast cancer or mastectomy. One patient reported taking medication regularly, specifically opioids in the form of codeine. Four patients had lesions in the left breast with one being lateral and three medial. The remaining three patients had lesions in the medial right breast.

### 3.1.2 | Phase I—Primary procedure outcomes and safety data

Of the seven biopsies performed by IGAR, none required conversion to a manual procedure and none needed to be repeated. All

procedures were successfully completed by IGAR and had a 95% CI of 0.65–1.00 (Table 2). No adverse events were reported in phase I (Table 3). There was a single device deficiency with IGAR in which there was an error with rolling the VAB tool (Table 4).

**TABLE 1** Patient demographics for Image Guided Automated Robot (IGAR)-Breast patients in the phase I trial

| Characteristic | IGAR-Breast |
|---|---|
| # of biopsies | 7 |
| Age, mean (SD) | 55.0 (14.0) |
| Weight, kg; mean (SD) | 58.6 (11.6) |
| BMI, kg/m$^2$; mean (SD) | 22.6 (4.6) |
| Ethnicity, *N* (%) | - |
| Caucasian | 7 (100) |
| Regular medication use, *N* (%) | 1 (14.3) |
| Location of breast lesion, *N* (%) | - |
| Left breast | |
| Lateral | 1 (14.3) |
| Medial | 3 (42.9) |
| Right breast | |
| Lateral | 0 |
| Medial | 3 (42.9) |

### 3.1.3 | Phase I—Secondary procedure outcomes

All patients received two anaesthetic injections of 5 ml each (Table 5). Additionally, all procedures only required one attempt to reach the target lesion. The mean subject time in the MRI suite was 72.9 ± 12.4 min. Average pain scores were 0 at both the time of the procedure and 1 week after. The median absolute positioning error of the IGAR obturator tip was 3.3 mm (IQR: 3.2–3.5). For each of the three-dimensional components of error, the median positioning error was 1.9 mm in the X dimension, 1.6 mm in the Y dimension, and 1.9 mm in the Z dimension (Table 5). There were no systematic targeting errors in positioning (Figure 4A,B).

Overall, the IGAR biopsies were well received by patients. All parameters of the acceptance questionnaire had a median score of '1—strongly agree,' except for bed comfort which had a median score of '2—agree' (Table 6). Patients also found the procedure to be tolerable and comfortable overall, which also had a median score of 1. Similarly, radiologists assessing the ease-of-use found the setup, patient positioning, application of breast compression, target selection, setup and removal of the anaesthesia adaptor, administering anaesthesia, setup and removal of the trocar tool adaptor and needle guide, and inserting the trocar were '2—easy' on average. Registering an image on the workstation, setup of the VAB tool adaptor, collecting samples with the VAB tool, retracting the cannula, and clean up were scored as '1—very easy' on average (Table 6).

**TABLE 2** Primary procedure outcomes for IGAR and manual biopsies in the phase I and II trials

| Metric | IGAR Phase I | IGAR Phase II | Manual Phase II | *p*-value |
|---|---|---|---|---|
| # of biopsies | 7 | 23 | 18 | - |
| # of converted biopsies | 0 | 3 | - | - |
| Successful biopsies, *N* (%) | 7 (100) | 19 (82.6) | 18 (100) | 0.118 |
| 95% CI | [0.65, 1.00] | [0.63, 0.93] | [0.82, 1.00] | - |

*Note*: The *p*-values are comparing IGAR to manual biopsies in phase II only.

**TABLE 3** Safety information including adverse events

| | IGAR Phase I | IGAR Phase II | Manual Phase II |
|---|---|---|---|
| Total adverse events | 0 | 7 | 3 |
| Potential breast implant rupture | 0 | 1 | 0 |
| Bleeding | 0 | 1 | 0 |
| Insufficient deep anaesthesia | 0 | 2 | 0 |
| Follow-up MRI | 0 | 1 | 0 |
| Discomfort | 0 | 1 | 0 |
| Repeat biopsy scheduled | 0 | 1 | 0 |
| Full period after irregular menstrual cycles | 0 | 0 | 1 |
| Nausea following saline injection | 0 | 0 | 1 |
| Rash from medical tape | 0 | 0 | 1 |

Abbreviations: IGAR, Guided Automated Robot; MRI, magnetic resonance imaging.

**TABLE 4** Device deficiencies experienced with the IGAR system during the phase I and II trials

| | IGAR Phase I | IGAR Phase II |
|---|---|---|
| Total device deficiencies | 1 | 9 |
| VAB tool rolling error | 1 | 3 |
| Needle retracting without injecting anaesthesia | 0 | 1 |
| Workstation could not validate target lesion | 0 | 1 |
| Recurrent collision error | 0 | 1 |
| Anaesthesia tool rolling error | 0 | 3 |

Abbreviations: IGAR, Guided Automated Robot; VAB, Vaccuum Assisted Biopsy.

**TABLE 5** Secondary outcomes for Image Guided Automated Robot (IGAR) and manual biopsies in the phase I and II trials

| Outcome measures | IGAR Phase I | IGAR Phase II | Manual Phase II | 95% CI | *p*-value |
|---|---|---|---|---|---|
| Procedure time (minutes)[a] | - | 55.7 ± 12.8 | 53.9 ± 27.5 | [−11.3, 14.9] | 0.804 |
| Total subject time in MRI suite (minutes) | 72.9 ± 12.4 | 70.5 ± 13.8 | 60.8 ± 26.0 | [−7.6, 26.9] | 0.252 |
| Patient pain at biopsy (max score 45) | 0 (0–1.5) | 0 (0–2.5) | 1 (0–5.25) | - | 0.170 |
| Patient pain after 1 week (max score 45) | 0 (0–0) | 0 (0–1) | 1 (0–2.75) | - | **0.027** |
| Scar 1 week (max score 14) | - | 1 (1–2) | 2 (1–3) | - | **0.035** |
| Scar 1 month (max score 14) | - | 0 (0–0.25) | 1 (0–4.25) | - | **0.004** |
| Number of attempts required to reach the target lesion | 1 (1–1) | 1 (1–1) | 1 (1–1) | - | 0.481 |
| Positioning error (mm)[b] | 3.3 (3.2–3.5) | 0.56 (−0.39 – 3.83) | | | |
| X | 1.9 (1.5–2.5) | 0 (−0.30 – 1.12) | | | |
| Y | 1.6 (1.25–1.7) | 0 (0–1.77) | | | |
| Z | 1.9 (1.3–2.0) | 0 (−0.03 – 1.67) | | | |
| # of anaesthetic injections | 2 (2–2) | 2 (2–2) | 2 (1–2) | - | **0.001** |
| 5 ml, *N* (%) | 14 (100) | 25 (55.6) | 9 (33.3) | - | **<0.001** |
| 8 ml, *N* (%) | 0 | 0 | 2 (7.4) | - | |
| 10 ml, *N* (%) | 0 | 19 (42.2) | 14 (51.9) | - | |
| 15 ml, *N* (%) | 0 | 1 (2.2) | 0 | - | |
| 17 ml, *N* (%) | 0 | 0 | 1 (3.7) | - | |
| 20 ml, *N* (%) | 0 | 0 | 1 (3.7) | - | |
| Total volume of anaesthetic (ml) | 10 (10–10) | 5 (5–10) | 10 (5–10) | - | 0.096 |
| First injection | 5 (5–5) | 5 (5–10) | 10 (5–10) | - | 0.137 |
| Second injection | 5 (5–5) | 5 (5–10) | 10 (5–10) | - | 0.618 |

*Note*: The *p*-values are comparing IGAR to manual biopsies in phase II only. The bolded *p*-values indicate statistical significance ($p < 0.05$).

[a]From first imaging session to last imaging session.

[b]Obturator tip compared to target lesion determined by MRI.

## 3.2 | Efficacy study—Phase II

There were 48 patients that consented during the Phase II IGAR clinical trial with 19 patients that had successful IGAR biopsies, 1 had an unsuccessful IGAR biopsy that needed to be repeated, 3 IGAR procedures were converted to manual, 18 had successful manual biopsies, and 5 had their procedures cancelled due to reasons unrelated to IGAR. One patient with two breast lesions and one patient where the MR table would not move into the bore were excluded.

### 3.2.1 | Phase II—Demographics

Table 7 describes and compares the demographics between IGAR and manual breast biopsy participants. There were 18 manual procedures, with 7 in Quebec and 11 in Hamilton ($p = 0.189$), and 23 robotic procedures using IGAR-Breast, with 22 in Quebec and 1 in Hamilton ($p < 0.001$), performed during these phase II trials. The average age for IGAR-Breast patients was 49 and 55 years for manual ($p = 0.178$). There were no significant differences in weight

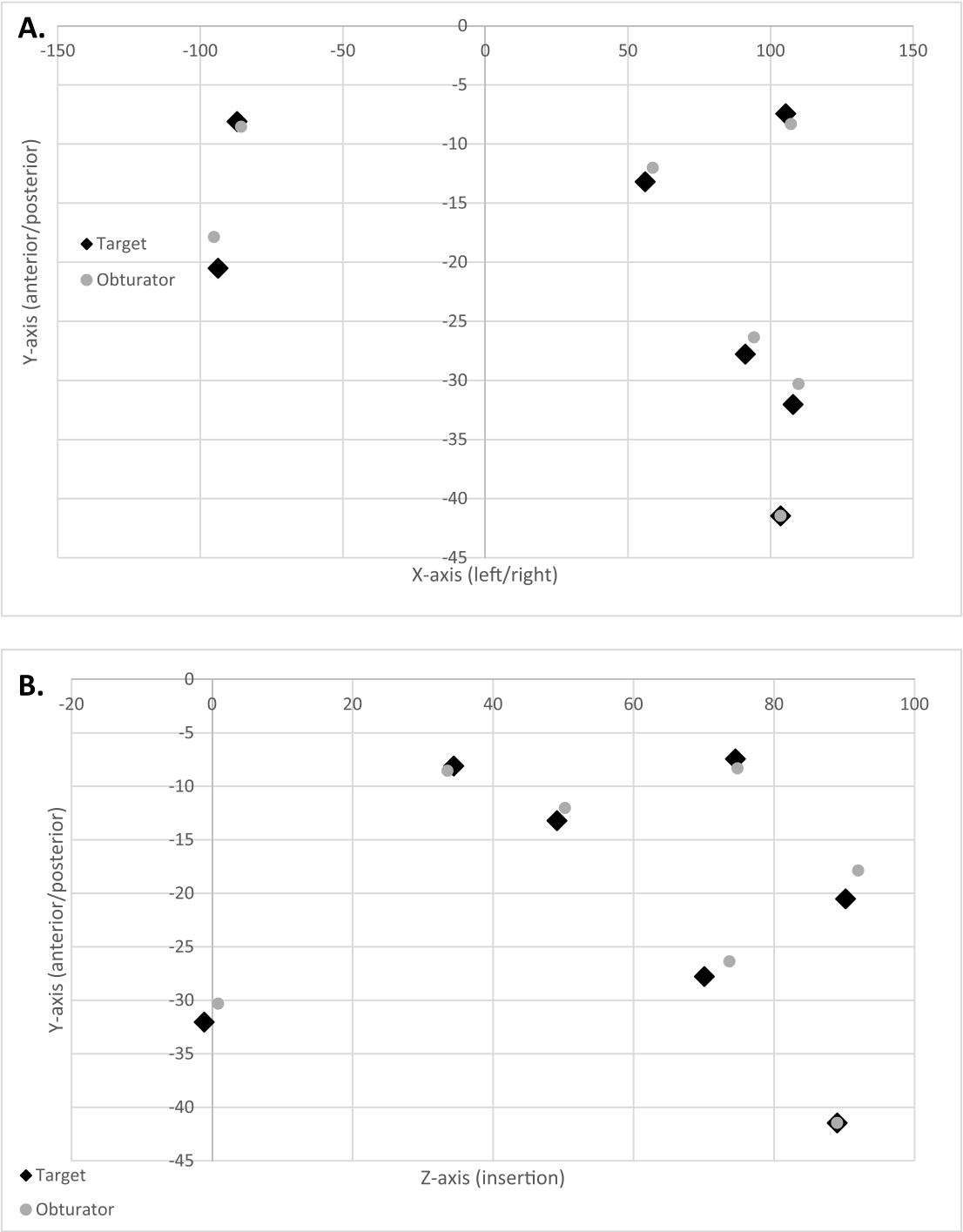


**FIGURE 4** Targeting accuracy of IGAR in phase I (A) from a superior view and (B) from a lateral view. Target coordinates (i.e., centre of suspicious lesion) are represented by black diamonds and the IGAR obturator tip coordinates are represented by grey circles

between IGAR and manual patients (63.8 vs. 74.1, $p = 0.058$). However, manual biopsy patients tended to have a higher BMI on average ($p = 0.017$). The largest patient that underwent a biopsy using IGAR was 230 lbs with a body mass index of 36 kg/m$^2$. The subjects were predominantly Caucasian and there were no significant proportional differences in ethnicity between the IGAR and manual biopsy recipients. There were no significant differences in history of breast cancer, benign breast lesions, or mastectomy between groups. In terms of medication use, 78.3% of IGAR-Breast patients compared to 61.1% of manual biopsy patients reported regularly taking medications ($p = 0.235$). On average, patients from both groups take between one and two medications regularly ($p = 0.312$). Additionally,

**TABLE 6** Discomfort and system ease-of-use based on the patient acceptance and radiologist usability questionnaires, respectively, for IGAR and manual biopsies in the phase I and II trials

| Discomfort parameter | IGAR Phase I | IGAR Phase II | Manual Phase II | *p*-value |
|---|---|---|---|---|
| Comfortable bed | 2 (1–2.5) | 2 (2–4) | 2 (1.5–2) | 0.075 |
| Acceptable noise level | 1 (1–1) | 1 (1–1) | 2 (1–2) | **0.030** |
| Tolerable breast compression | 1 (1–2.5) | 1 (1–2) | 2 (1–2) | 0.106 |
| Tolerable anaesthetic injection | 1 (1–2.5) | 1 (1–2) | 2 (1–2) | 0.512 |
| Tolerable biopsy tools insertion | 1 (1–2.5) | 1 (1–1) | 2 (1–2) | **0.009** |
| *IGAR only*: Comfortable robot position | 1 (1–1) | 2 (1–2.25) | - | - |
| Overall: Procedure tolerable | 1 (1–1) | 1 (1–1) | 2 (1–2) | **0.020** |
| Overall: Comfortable during procedure | 1 (1–1) | 1 (1–2) | 1 (1–2) | 0.127 |
| Ease-of-use parameter | | | | |
| Setup | 2 (1.75–2.25) | 1 (1–1) | 1 (1–2) | **0.048** |
| Positioning the patient | 2 (1–3) | 1 (1–1) | 2 (1.25–2) | **0.002** |
| Application of breast compression | 2 (1–2.5) | 1 (1–1) | 1.5 (1–2.75) | **0.026** |
| *IGAR only*: Registering image on workstation | 1 (1–1) | 1 (1–1) | - | - |
| *IGAR only*: Target selection on workstation | 2 (1–3) | 1 (1–1) | - | - |
| *IGAR only*: Setup/removal of anaesthesia adaptor tool | 2 (1–3) | 1 (1–1) | - | - |
| Administering anaesthesia | 2 (1.5–2.5) | 1 (1–2) | 1 (1–2) | 0.974 |
| *IGAR only*: Setup/removal of trocar tool adaptor and needle guide | 2 (1–2) | 1 (1–1) | - | - |
| Inserting trocar | 2 (1.25–2.75) | 1 (1–1) | 1 (1–2) | **0.002** |
| *IGAR only*: Setup of VAB tool adaptor | 1 (1–1.5) | 1 (1–1) | - | - |
| Inserting and rolling VAB tool | 1 (1–1) | 1 (1–1.75) | 2 (1–2) | 0.273 |
| Collecting samples with VAB tool | 1 (1–1) | 1 (1–1) | 2 (1–2) | **0.004** |
| Retracting cannula | 1 (1–1.75) | 1 (1–1) | 2 (1–2) | **0.003** |
| Clean up | 1 (1–1) | 1 (1–1) | 1 (1–2) | **0.003** |

*Note*: Acceptance questionnaire uses a scale of 1–5, with 1 being 'strongly agree' and 5 being 'strongly disagree'. Ease-of-use questionnaire uses a scale of 1–5, with 1 being 'very easy' and 5 being 'very difficult.' The *p*-values are comparing IGAR to manual biopsies in phase II only. The bolded *p*-values indicate statistical significance ($p < 0.05$).

Abbreviations: IGAR, Image Guided Automated Robot; VAB, vaccumm-assisted biopsy.

there were no differences in the location of breast lesions between the two groups.

### 3.2.2 | Phase II—Primary procedure outcomes

Of the 23 biopsies performed using IGAR-Breast, there were four unsuccessful biopsies. One IGAR patient required a repeat biopsy. Three biopsies were converted from IGAR to manual due to (1) an unreachable lesion, (2) failure to align due to a self collision, and (3) the VAB tools would not roll. In one case, the MR table would not move into the bore prior to the procedure and thus this case was excluded from analysis. Otherwise, all biopsies using either IGAR or manual were successful. There were no differences in biopsy success between IGAR and manual ($p = 0.118$). The 95% CIs for biopsy success were similar between IGAR and manual with 0.63–0.93 and 0.82–1.00, respectively.

### 3.2.3 | Phase II—Safety data

Overall, 10 adverse events were reported during the trials with seven in IGAR patients and three in manual patients ($p = 0.317$; Table 3). Adverse events included potential breast implant rupture, a follow-up MRI, discomfort, bleeding, insufficient deep anaesthesia, a full period after irregular menstrual cycles, nausea following saline injection, and a rash from medical tape. There were no serious adverse events reported. Further, there were nine device deficiencies with IGAR in phase II, including three errors with VAB tool rolling, one needle retraction without injecting anaesthesia, one case where the

**TABLE 7** Patient demographics for Image Guided Automated Robot (IGAR)-Breast and manual biopsy patients in the phase II trial

| Characteristic | IGAR-breast biopsy | Manual breast biopsy | *p*-value |
|---|---|---|---|
| Age, mean (SD) | 49.0 (13.3) | 54.8 (13.6) | 0.178 |
| Weight, kg; mean (SD) | 63.8 (13.9) | 74.1 (19.8) | 0.058 |
| BMI, kg/m$^2$; mean (SD) | 23.4 (4.7) | 27.8 (6.6) | **0.017** |
| # of biopsies | 23 | 18 | - |
| Ethnicity, *N* (%) | | | |
| Caucasian | 23 (100) | 17 (94.4) | 0.256 |
| Hispanic/Latino | 0 | 1 (5.6) | 0.256 |
| Medical history, *N* (%) | | | |
| Breast cancer | 5 (21.7) | 5 (27.8) | 0.656 |
| Breast fibroadenoma | 2 (8.7) | 0 | 0.205 |
| Partial mastectomy | 0 | 2 (11.1) | 0.106 |
| Regular medication use, *N* (%) | 18 (78.3) | 11 (61.1) | 0.235 |
| Average # of medications, mean (SD) | 1.7 (1.4) | 1.3 (1.4) | 0.312 |
| Location of breast lesion, *N* (%) | | | |
| Left breast | | | |
| Lateral | 3 (13.0) | 5 (27.8) | 0.241 |
| Medial | 6 (26.1) | 1 (5.6) | 0.088 |
| Right breast | | | |
| Lateral | 9 (39.1) | 8 (44.4) | 0.736 |
| Medial | 4 (17.4) | 3 (16.7) | 0.954 |
| Not recorded | 1 (4.3) | 1 (5.6) | 0.850 |

*Note*: The bolded *p*-values indicate statistical significance ($p < 0.05$).

workstation could not validate the target lesion identified by the radiologist, one recurrent collision error, and three errors with anaesthesia tool rolling (Table 4). While both IGAR and manual patients received two anaesthetic injections on average, manual patients received fewer anaesthetic injections overall (Table 5, $p = 0.001$).

### 3.2.4 | Phase II—Secondary procedure outcomes

Procedure time as well as total subject time in the MRI suite were similar for both IGAR and manual biopsy procedures with a mean procedure time of 55.7 ± 12.8 min and 53.9 ± 27.5 min, respectively ($p = 0.804$), and an average subject time in the MRI suite of 70.5 ± 13.8 min for IGAR and 60.8 ± 26.0 min for manual ($p = 0.252$). Notably, there was a larger variance with manual biopsies in terms of both the procedure time ($V_{IGAR} = 163.2$, $V_{manual} = 758.7$, $p = 0.007$) and the total time the subject was in the MRI suite ($V_{IGAR} = 189.3$, $V_{manual} = 678.0$, $p = 0.011$). On average, healthcare providers were able to reach the target lesion in a single attempt using either IGAR and manual ($p = 0.481$). Patient pain at the time of biopsy was comparable between IGAR and manual (Table 5; $p = 0.170$); however, at 1 week after biopsy, pain scores were significantly lower in the patients that received a biopsy by IGAR versus those that had a manual biopsy ($p = 0.027$). Moreover, scar scores at both 1 week and 1 month after biopsy had better cosmetic outcomes in IGAR patients compared to manual biopsy patients ($p = 0.035$ and $p = 0.004$, respectively).

The median absolute positioning error of the IGAR obturator tip was 0.56 mm (IQR: −0.39–3.83). For each of the three-dimensional components of error, the median positioning error was 0 mm (Table 5). There were no systematic errors or large discrepancies between target coordinates and the obturator tip during any of the biopsies (Figures 5A,B).

Generally, measures of discomfort assessed by patients were comparable between IGAR and manual (Table 6). However, IGAR patients found that the noise level ($p = 0.030$), insertion of the biopsy tools ($p = 0.009$), and the overall procedure ($p = 0.020$) were more tolerable than those that had a manual biopsy. Ease-of-use evaluated by the radiologists found that use was generally easier with IGAR compared to manual biopsy (Table 6). Notably, procedure setup ($p = 0.048$), patient positioning ($p = 0.002$), application of breast compression ($p = 0.026$), inserting the trocar ($p = 0.002$), collecting samples with the VAB tool ($p = 0.004$), retracting the cannula ($p = 0.003$), and clean up ($p = 0.003$) were all easier with IGAR compared to the manual biopsy procedures.

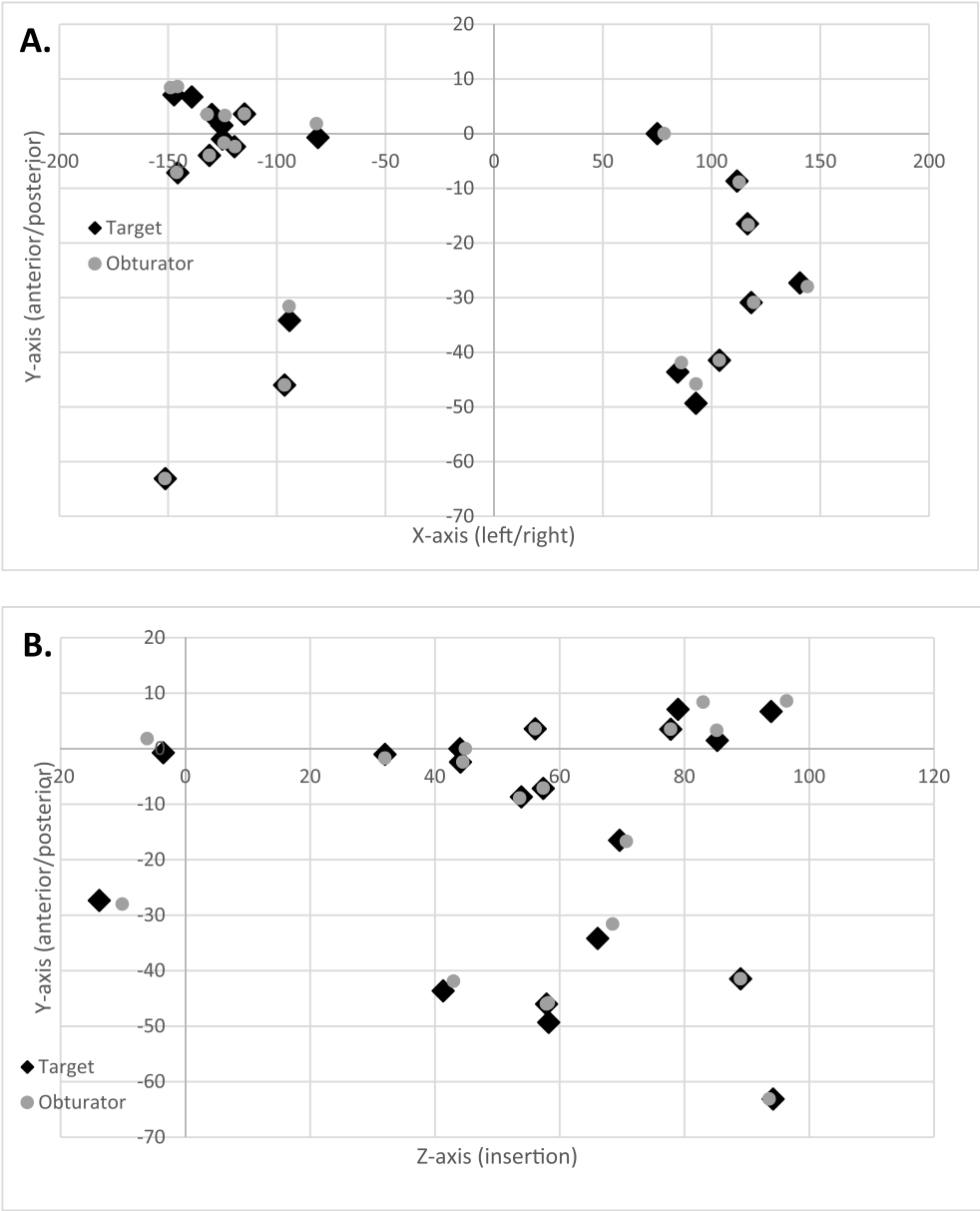


**FIGURE 5** Targeting accuracy of Image Guided Automated Robot (IGAR) in phase II (A) from a superior view and (B) from a lateral view. Target coordinates (i.e., centre of suspicious lesion) are represented by black diamonds and the IGAR obturator tip coordinates are represented by grey circles.

## 4 | DISCUSSION

We have developed an automated robot that is capable of safely and effectively performing a MRI-guided biopsy while the patient is on the MR table. Our results demonstrate that the robot is capable of achieving results equivalent to or better than a skilled MR breast interventional radiologist with a high degree of success.

IGAR biopsies had comparable, but more consistent, procedure times and total time the subject was in the MRI suite. Increased IGAR procedure times reflect the learning curve as well as minor changes implemented to improve the system. IGAR procedure times decreased from phase I to phase II and we expect these times to decrease further, possibly shorter than manual biopsies, with more experience as users become familiar with the IGAR system.

IGAR was able to outperform manual biopsy in pain scores at 1 week after the procedure, cosmetic outcome for scarring at both 1 week and 1 month after the procedure, patient comfort with noise level, biopsy tool insertion, and tolerating the procedure overall, as well as the setup, patient positioning, application of breast compression, inserting the trocar, collecting samples with the VAB tool, retracting the cannula, and clean up determined by radiologists. This was all also accomplished with no adverse events in the phase I trial and minimal adverse events including no serious adverse events in the phase II trial, ultimately indicating that the IGAR system is not only effective, but safe for breast biopsy procedures. A shift from

manual to automated procedures will not only reduce the learning curve for procedures, but provide an unbiased and objective approach to healthcare. Similar designs using artificial intelligence to shift further from automated to autonomous procedures and adapt in real time will only improve upon the results of this study.

Clearly, the system is still being improved to overcome minor software issues encountered during phase II studies, but we are encouraged by the patient acceptance of this technology and the improved pain and cosmetic scores which suggest a better patient experience for such an invasive procedure. Although the procedure time was not significantly different between robotic and manual procedures, we believe with increased use and improvements to the system, we will be able to shorten the biopsy time and thus reduce the total time in the MR room.

In an attempt to increase access to healthcare in regions where healthcare resources and professionals are limited, we plan on equipping IGAR with tele-operation. Tele-operable capabilities will allow for a potential improvement in access to higher quality healthcare that does not require the provider to be in the same room as the patient. Our future plans include presenting results from our study with IGAR using teleoperation.

It is important to note the potential limitations of this study and the IGAR system as this may impact the patient population that is available for treatment using this technology. Factors including size of the patient, breast size, or location of the breast lesion may prevent some patients from being candidates for breast biopsy using the current model of IGAR. The clinician performing biopsies in Hamilton used a skin nick technique for at least one IGAR biopsy which might increase pain or scarring; however, since the incision is usually small and superficial, this is unlikely. The choice of using a skin nick is based on physician preference and a factor in this decision is the sharpness of the introducer. In spite of this, IGAR still had lower pain and scar scores compared to the manual procedures.

The IGAR-Breast system provides a safe and effective alternative in order to streamline breast cancer biopsy procedures. Initial results show reduced pain and scarring with IGAR-Breast compared to standard of care manual procedures, as well as superior patient comfort with the procedure and radiologist ease-of-use.

## ACKNOWLEDGEMENTS

The authors would like to thank the clinicians for their assistance in performing the manual and IGAR procedures described in these trials, including Dr. Nathalie Duchesne and Dr. Colm Boylan.

## CONFLICT OF INTEREST

Mehran Anvari is the Scientific Director and CEO of the Centre for Surgical Invention and Innovation (CSii), and shareholder of Insight Medbotics. Tim Fielding lead the IGAR development team at MDA.

## DATA AVAILABILITY STATEMENT

The data that support the findings of this study are available on request from the corresponding author. The data are not publicly available due to privacy or ethical restrictions.

## ORCID

*Mehran Anvari* https://orcid.org/0000-0001-7256-5789
*Karen Barlow* https://orcid.org/0000-0001-6681-6668

## REFERENCES

1. Canadian Cancer Society. Breast Cancer Statistics. Accessed October 18, 2021. https://cancer.ca/en/cancer-information/cancer-types/breast/statistics
2. Schneider AP II, Zainer CM, Kubat CK, Mullen NK, Windisch AK. The breast cancer epidemic: 10 facts. *Linacre Q*. 2014;81(3):277. https://doi.org/10.1179/2050854914Y.0000000027
3. Kerlikowske K, Hubbard RA, Miglioretti DL, et al. Comparative effectiveness of digital versus film-screen mammography in community practice in the United States: a cohort study. *Ann Intern Med*. 2011;155(8):502. https://doi.org/10.7326/0003-4819-155-8-201110180-00005
4. Lynge E, Vejborg I, Andersen Z, von Euler-Chelpin M, Napolitano G. Mammographic density and screening sensitivity, breast cancer incidence and associated risk factors in Danish breast cancer screening. *J Clin Med*. 2019;8(11):2021. https://doi.org/10.3390/JCM8112021
5. Cancer Care Ontario. Breast Cancer Screening for Women at High Risk. Accessed October, 3 2021. https://www.cancercareontario.ca/en/guidelines-advice/cancer-continuum/screening/breast-cancer-high-risk-women
6. Wiratkapun C, Duke D, Nordmann AS, et al. Indeterminate or suspicious breast lesions detected initially with MR imaging: value of MRI-directed breast ultrasound. *Acad Radiol*. 2008;15(5):618-625. https://doi.org/10.1016/J.ACRA.2007.10.016
7. Wiener JI, Schilling KJ, Adami C, Obuchowski NA. Assessment of suspected breast cancer by MRI: a prospective clinical trial using a combined kinetic and morphologic analysis. *Am J Roentgenol*. 2012;184(3):878-886. https://doi.org/10.2214/AJR.184.3.01840878
8. Berg B, Zhang Z, Lehrer D, et al. Detection of breast cancer with addition of annual screening ultrasound or a single screening MRI to mammography in women with elevated breast cancer risk. *JAMA*. 2012;307(13):1394-1404. https://doi.org/10.1001/JAMA.2012.388
9. Lehman CD, DePeri ER, Peacock S, McDonough MD, DeMartini WB, Shook J. Clinical experience with MRI-guided vacuum-assisted breast biopsy. *Am J Roentgenol*. 2012;184(6):1782-1787. https://doi.org/10.2214/AJR.184.6.01841782
10. Velanovich V, Lewis FR, Jr., Nathanson SD, et al. Comparison of mammographically guided breast biopsy techniques. *Ann Surg*. 1999;229(5):625. https://doi.org/10.1097/00000658-199905000-00004
11. Sakamoto N, Tozaki M, Higa K, Abe S, Ozaki S, Fukuma E. False-negative ultrasound-guided vacuum-assisted biopsy of the breast: difference with US-detected and MRI-detected lesions. *Breast Cancer*. 2009;17(2):110-117. https://doi.org/10.1007/S12282-009-0112-1
12. Youk JH, Kim EK, Kim MJ, Lee JY, Oh KK. Missed breast cancers at US-guided core needle biopsy: how to reduce them. *Radiographics*. 2007;27(1):79-94. https://doi.org/10.1148/RG.271065029
13. Monfaredi R, Cleary K, Sharma K. MRI robots for needle-based interventions: systems and technology. *Ann Biomed Eng*. 2018;46(10):1479-1497. https://doi.org/10.1007/s10439-018-2075-x
14. Miah S, Servian P, Patel A, et al. A prospective analysis of robotic targeted MRI-US fusion prostate biopsy using the centroid targeting approach. *J Robot Surg*. 2020;14(1):69-74. https://doi.org/10.1007/s11701-019-00929-y
15. Patel NA, Li G, Shang W, et al. System integration and preliminary clinical evaluation of a robotic system for MRI-guided transperineal

prostate biopsy. *J Med Robot Res*. 2019;04(02):1950001. https://doi.org/10.1142/S2424905X19500016

16. Zhang T, Wen Y, Liu YH. Developing a parallel robot for MRI-guided breast intervention. *IEEE Trans Med Robot Bion*. 2020;2(1):17-27. https://doi.org/10.1109/TMRB.2019.2957566
17. Squires A, Oshinski JN, Boulis NM, Tse ZTH. SpinoBot: an MRI-guided needle positioning system for spinal cellular therapeutics. *Ann Biomed Eng*. 2018;46(3):475-487. https://doi.org/10.1007/s10439-017-1960-z
18. Franco E, Brujic D, Rea M, Gedroyc WM, Ristic M. Needle-guiding robot for laser ablation of liver tumors under MRI guidance. *IEEE/ASME Trans Mechatron*. 2016;21(2):931-944. https://doi.org/10.1109/TMECH.2015.2476556
19. Nycz CJ, Gondokaryono R, Carvalho P, et al. Mechanical validation of an MRI compatible stereotactic neurosurgery robot in preparation for pre-clinical trials. In: *2017 IEEE/RSJ International Conference on Intelligent Robots and Systems (IROS)*. IEEE; 2017:1677-1684. https://doi.org/10.1109/IROS.2017.8205979
20. Chan KG, Fielding T, Anvari M. An image-guided automated robot for MRI breast biopsy. *Int J Med Robot Comput Assist Surg*. 2016;12(3):461-477. https://doi.org/10.1002/rcs.1760
21. Melzack R. The short-form McGill pain questionnaire. *Pain*. 1987;30(2):191-197. https://doi.org/10.1016/0304-3959(87)91074-8
22. Sullivan T, Smith J, Kermode J, McIver E, Courtemanche D. Rating the burn scar. *J Burn Care Rehabil*. 1990;11(3):256-260. https://doi.org/10.1097/00004630-199005000-00014

**How to cite this article:** Anvari M, Chapman T, Barlow K, Cookson T, Van Toen C, Fielding T. Clinical safety and efficacy of a fully automated robot for magnetic resonance imaging-guided breast biopsy. *Int J Med Robot*. 2022;e2472. https://doi.org/10.1002/rcs.2472